

Changes in the Visual Cortex in Patients with Normotensive Glaucoma

Jan Lešták^{1,2,3*}, Jaroslav Tintěra¹, Lukáš Ettlér¹, Elena Nutterová¹ and Pavel Rozsival³¹JL Clinic, V Hůrkách 1296/10, Prague, Czech Republic²Czech Technical University in Prague (Faculty of Biomedical Engineering)³Charles University (Faculty of Medicine in Hradec Králové)**Abstract**

Objective: To show whether there is a correlation between visual field changes in normotensive glaucoma and changes in functional magnetic resonance of the visual cortex.

Methods and subjects: The authors examined eight normotensive glaucoma patients (stage initial to medium) by means of functional magnetic resonance imaging (fMRI). Measurements were performed on a Philips Achieva 3T TX MR system using the BOLD method. For visual stimulation, a black and white checkerboard with an alternating negativity frequency of 2 Hz was used. Each measurement consisted of a block scheme with 5 intervals of an active phase lasting 30s followed by 5 resting intervals of equal duration. The measured data were processed on SPM software.

A comprehensive ophthalmological examination was supplemented by an examination of the visual field by means of a fast threshold program. The sum of sensitivity in the field of vision homolateral halves (range 0 to 22 degrees) was compared with a range of fMRI activity contra lateral visual cortex. Data collected from the patients were compared with a group of eight healthy controls.

Results: The collected data was subjected to statistical analysis (nonparametric Spearman's Rank Correlation Coefficient) which showed a weak indirect correlation between changes in the field of vision and changes in the visual cortex. $R=-0,270$ ($p=0,558$), $R=-0,071$ ($p=0,879$) respectively.

Conclusion: The authors demonstrated that in the patients with normotensive glaucoma there are no corresponding functional changes in the cerebral cortex, unlike hypertensive glaucoma where the advanced stage of glaucoma changes was associated with lower activation of the visual cortex. They assume that normotensive glaucoma has different pathogenetic behavior than hypertensive glaucoma.

Keywords: Normotensive glaucoma; Changes in the visual field; Visual cortex; fMRI

Introduction

It is generally acknowledged that there are differences between normotensive glaucoma and hypertensive glaucoma, not only in terms of intraocular pressure but also in terms of the nature of changes to the field of vision; changes, for example, which extend more towards the center and result in more significant decreases insensitivity [1-3]. Some of the typical differences are: the nerve fibers interferes more with the center of the retina and has a focal character [4]; there is larger and deeper excavation while the lamina cribrosa is thinner [5,6]; vasospasms [7]; nights systemic hypotension, reduced ocular pulse amplitude and fluctuation of eye perfuse pressure [8-11]; narrowed retinal veins; worsening hem or hologic qualities of blood [12,13] etc. The idea that the diseases may not be the same is a problem we have been dealing with for years. So far, we have managed to prove differences at the level of visual pathway damage [14]. This conclusion is also supported by changes in the visual cortex demonstrated in hypertensive glaucomas by fMRI [15]. In this study, where we were looking into the dependence of changes in the fields of vision on the fMRI of the visual cortex in hypertensive glaucomas, we proved a medium degree of dependence. Now we have attempted to find out whether this dependence is also valid in normotensive glaucoma.

Subjects and methodology

Eight patients with normotensive glaucoma (6 females aged 53-70 and 2 males aged 40 and 52 years) were included in our research group.

The inclusion criteria were the following: normal visual acuity, bilateral disorder, various changes in the field of vision (pattern defect

1.12-12.65). Other causes of changes in the fields of vision and on the optic nerve disc were excluded. Basic information on the patients is shown in Table 1.

The results were compared with a control group of eight healthy subjects (3 females aged 23-46 and 5 males aged 23-65 years). We are aware of the difference in sexes of both groups, but the control group was used for the previous study as well where the representation of

Gender	Years	IOP RE	IOP LE
F	64	12	12
F	60	17	17
F	70	10	12
F	70	12	12
F	53	13	14
F	70	11	14
M	52	14	13
M	40	11	14

Table 1: The group consisted of six females and two males. The value of IOP is in mmHg.

***Corresponding author:** TJan Lešták, JL Clinic, V Hůrkách 1296/10, Prague, Czech Republic, E-mail: lestak@seznam.cz

Received June 07, 2012; **Accepted** July 20, 2012; **Published** July 25, 2012

Citation: Lešták J, Tintěra J, Ettlér L, Nutterová E, Rozsival P (2012) Changes in the Visual Cortex in Patients with Normotensive Glaucoma. J Clin Exp Ophthalmol S4:008. doi:10.4172/2155-9570.S4-008

Copyright: © 2012 Lešták J, et al. This is an open-access article distributed under the terms of the Creative Commons Attribution License, which permits unrestricted use, distribution, and reproduction in any medium, provided the original author and source are credited.

both sexes was about the same [15].

A possible dependence between changes in the fields of vision and changes in the brain were assessed using correlation coefficients arranged in a correlation matrix. Statistical processing was performed by the nonparametric Spearman's Rank Correlation Coefficient.

According to the correlation coefficient it is possible to distinguish among the following: weak ($|R| < 0.3$), medium ($0.3 < |R| < 0.8$) and strong ($|R| > 0.8$) dependence (correlation).

Functional MRI imaging

All the measurements of functional MR Imaging (fMRI) were performed on a Philips Achieva TXSERIES with a magnetic field strength of 3 Tesla. A standard 8-channel SENSE head RF coil was used for scanning. Optical stimulation with fMRI was performed with a commercially available Eyes (*In vivo*) stimulus system. For measuring fMRI with the BOLD technique the sequence of gradient echo EPI was used with the following parameters: TE = 30 ms, TR = 3s, 90° tilting angle. The measured volume contained 39 continuous 2mm-thick layers. The voxel size measured (spatial distinction) was 2x 2mm (FOV = 208x 208mm, matrix 04 x104, reconstruction matrix 128 x128, SENSE factor 1.8). fMRI was performed on all subjects. During fMRI scanning, a checkerboard of alternating black and white was projected to all subjects (Figure 1). This alternation is a color inversion with a frequency of 2 Hz. During their sting phase, a static cross hair situated in the center of the visible field was projected to each subject. Each measurement consisted of a block scheme with 5 active intervals lasting 30 s (10 dynamic scans) and 5 resting intervals of equal duration. In total, every measurement included 100 dynamics and took 5 minutes.

Figure 1 shows the black and white checker board (BW) used for stimulation. During the stimulation the checkerboard picture was alternated with its inversion with a frequency of 2 Hz.

The fMRI evaluation was performed with SPM8 software. During the pre-process, the data were corrected due to movement (realignment) and time-shift of individual layers (slice timing), and then smoothed with a Gaussian filter (smoothing) with FWHM 6 x 6 x 6 mm and finally standardized into the MNI_152 space. For statistics on the level of individual subjects the generally near model with universal HRF (hemodynamic response function) applied to the block scheme of stimulation was used. Statistical maps were then holded at $p = 0.05$ with few corrections. Group statistics was performed using unpaired t-test with an uncorrected threshold of $p = 0.005$ and a minimum number of contiguous voxels 50 (8 subjects in each group).

Ophthalmological examination

Complex ophthalmological examination was complemented by field of vision with glaucoma program in the regime of fast threshold program (Med mont M700, visual acuity was corrected to the near). The sum of sensitivity of homo lateral halves of fields of vision in the scope (0–22 degrees) was compared to the results of contra lateral activity fMRI of visual cortex. The table 1 shows age and the intraocular pressure values (mmHg). Visual acuity was 1.0 after correction.

Results

Table 1 the group consisted of six females and two males. The value of IOP is in mmHg.

The following tables (Tables 2-5) show the mathematical mean, median and standard deviation of the measured parameters both in the control group and in the patients (field of vision and fMRI).

The resulting correlation coefficient between right halves of the fields of vision and the scope of MRI activation on the left was -0.27 ($p = 0.558$); the correlation coefficient between the left halves of the field of vision and fMRI activation on the right was equal to -0.071 ($p = 0.879$), indicating a weak indirect correlation. The relationship between the visual field and hemispheric activation is weak and statistically inconclusive.

fMRI activation in the visual cortex of healthy individuals is shown in Figure 2. The following figure (Figure 3) shows that even with changes in the fields of vision (Figure 4) there is no decrease in fMRI activation.

Discussion

Work dealing with functional magnetic resonance imaging in normotensive glaucoma has yet to be found in any literature. Even knowledge of fMRI in hypertensive glaucoma [15-17] is unsatisfactory. All previous studies have proved changes in the visual cortex in human glaucoma.

In our study of patients with normotensive glaucoma (with various changes in the field of vision), our goal was to establish whether there is a relationship between the changes in the field of vision and the changes in functional MRI in the visual cortex. This idea of possible difference of hypertensive glaucomas from normotensive glaucoma has occupied our minds for years. Our suspicion of this difference is supported by years of experience with measuring of PERG and VEP in both of the groups. One of the outcomes is a paper demonstrating this




Figure 1: The figure Shows the black and white checker board (BW) used for stimulation. During the stimulation the checker board picture was alternated with its inversion with a frequency of 2 Hz.

	Average	Median	Standard deviation
Control group	2200.3	2196.5	59.6
Patients	1905.4	1875	301.4

Table 2: Right halves of the fields of vision (the sum of sensitivity in dB).

Control group	2165.8	2176	69.5
Patients	1894.3	2026	307.5

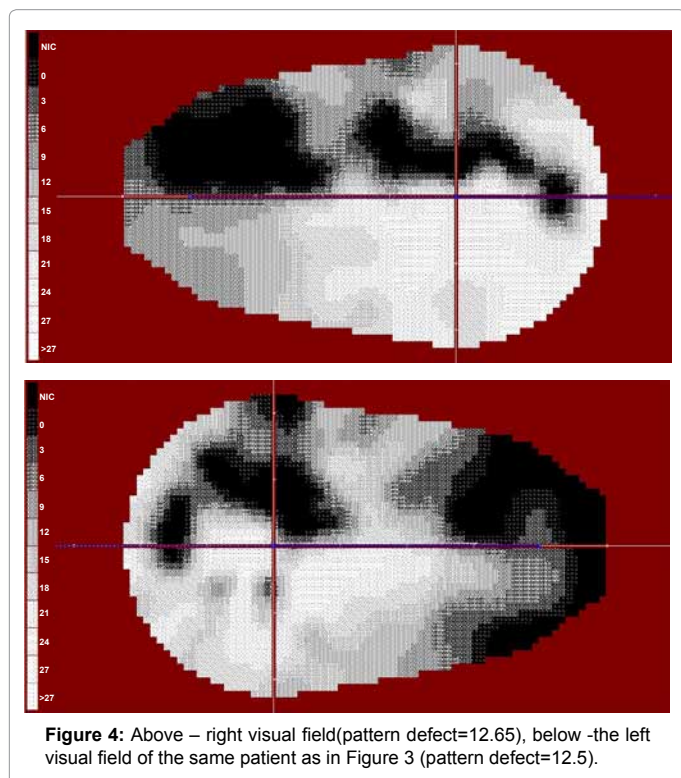
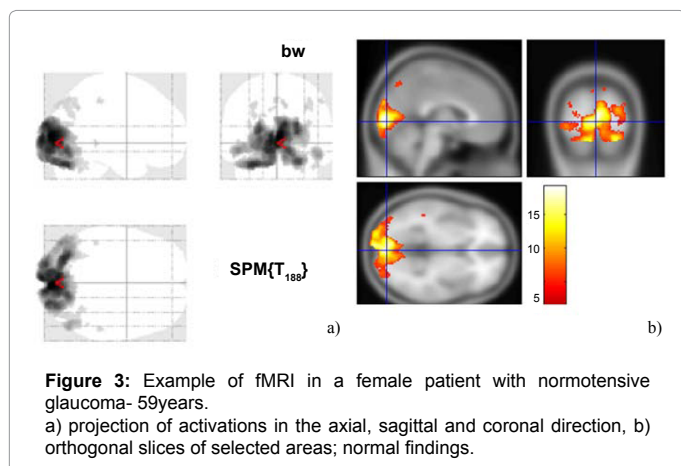
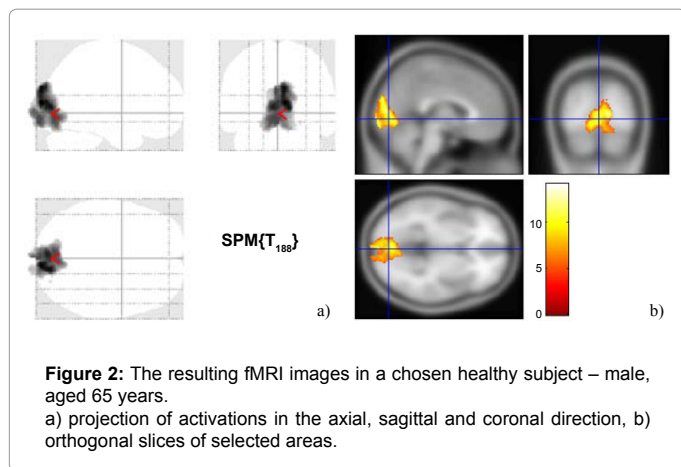
Table 3: Right halves of the fields of vision (the sum of sensitivity in dB).

Control group	4181.5	3445.5	2366.0
Patients	3398.4	3956	1718.8

Table 4: fMRI of left occipital hemispheres (sum of voxels).

Control group	4414.6	4093	2280.8
Patients	3262.3	3660	1727.9

Table 5: fMRI of right occipital hemisphere (sum of voxels).



difference [14].

Animal models with hypertensive glaucoma suggest that retinal ganglion cells negatively affect V1 cells with trans synaptic degeneration. However, very few reports have demonstrated the same results in humans.

Trans synaptic degeneration can play a role in animal models of glaucoma [18,19]. The death of retinal ganglion cells can quickly activate a cascade of processes along retinal-cortical pathways, processes which have neuro chemical [20], metabolic [21,22], functional [23], and neuro pathological consequences for the corpus geniculatum lateral and V1 cells. These processes may result in neuron loss and ultimately in shrinkage [24-26]. In normotensive glaucoma there is no direct damage to retinal ganglion cells [14]. The pathology is mainly in the visual pathway. Changes in the fields of vision due to normotensive glaucoma probably arise as a result of loss of retinal ganglion cell axons, and this decrease causes the excavation. In hypertensive glaucoma the decrease of ganglion cells in the retina occurs in the initial stages. Therefore, the nature of changes in the fields of vision in both diagnostic groups differs as well. Hence it can be assumed that in normotensive glaucoma's no changes of activation occur in the visual cortex.

In our group, where the sum of sensitivity in the homo lateral halves of the fields of vision with fMRI activation was compared, we did not statistically demonstrate a significant relationship. The resulting correlation coefficient between the right halves of the fields of vision and the scope fMRI activation on the left was -0.27 (p =0.558). The correlation coefficient between the left halves of the fields of vision and fMRI activation of the right was equal to -0.071 (p =0.879).

We are aware that our group is not large. There are also other studies dealing with similar numbers of examined patients [16,17]. The representation of both sexes is not uniform as well. This is due to higher incidence rate of normotensive glaucoma in females than in men. However, our assumption is based on our previous study [12] where we compared a group of 8 healthy subjects (3 females and 5 males) with a group of 9 hypertensive glaucoma's (3 females and 6 males). The intention was to compare what kind of activation of the visual cortex will there be in both diagnostic groups. Despite this information the statistical investigation did not prove any difference between the patients and the controls. Figure 3 and Figure 4 demonstrates that even with large changes in the fields of vision the activity of the visual cortex is without any alteration. Similar changes in the fields of vision in hypertensive glaucoma's would induce pronounced alteration in the activation of the visual cortex [15].

Shields define normotensive glaucoma as one of the most common forms of open-angle glaucoma [27]. We do not share this view; we feel that these are two separate etiopathogenetic diagnostic groups. This is also supported by the facts presented above. We know that it will not be easy to make ophthalmology community accept this new information. Our aim is to proceed with this activity to prove that our assertion is true.

Conclusion

The authors demonstrated that in the patients with normotensive glaucoma there are no corresponding functional changes in the cerebral cortex, unlike hypertensive glaucoma where the advanced stage of glaucoma changes was associated with lower activation of the visual cortex. They assume that normotensive glaucoma has different

pathogenetic behavior than hypertensive glaucoma.

References

1. Araie M, Yamagami J, Suzuki Y (1993) Visual field defects in normal-tension and high-tension glaucoma. *Ophthalmology* 100: 1808-1814.
2. Chang M, Yoo C, Kim SW, Kim YY (2011) Retinal vessel diameter, retinal nerve fiber layer thickness, and intraocular pressure in Korean patients with normal-tension glaucoma. *Am J Ophthalmol* 151: 100-105.
3. Cheng HC, Chan CM, Yeh SI, Yu JH, Liu DZ (2011) The hemorheological mechanisms in normal tension glaucoma. *Curr Eye Res* 36: 647-653.
4. Crawford ML, Harwerth RS, Smith EL 3rd, Shen F, Carter-Dawson L (2000) Glaucoma in primates: Cytochrome oxidase reactivity in parvo- and magnocellular pathways. *Invest Ophthalmol Vis Sci* 41: 1791-1802.
5. Crawford ML, Harwerth RS, Smith EL 3rd, Mills S, Ewing B (2001) Experimental glaucoma in primates: changes in cytochrome oxidase blobs in V1 cortex. *Invest Ophthalmol Vis Sci* 42: 358-364.
6. Duncan RO, Sample PA, Weinreb RN, Bowd C, Zangwill LM (2007) Retinotopic Organization of Primary Visual Cortex in Glaucoma: Comparing fMRI Measurements of Cortical Function with Visual Field Loss. *Prog Retin Eye Res* 26: 38-56.
7. Eid TE, Spaeth GL, Moster MR, Augsburger JJ (1997) Quantitative differences between the optic nerve head and peripapillary retina in low-tension glaucoma and high-tension primary open-angle glaucoma. *Am J Ophthalmol* 12: 805-813.
8. Flammer J, Prünke C (1991) Ocular vasospasm. 1: Functional circulatory disorders in the visual system, a working hypothesis. *Klin Monbl Augenheilkd* 198: 411-412.
9. Gupta N, Yucel YH (2001) Glaucoma and the brain. *J Glaucoma* 10: S28-S29.
10. Gupta N, Yucel YH (2003) Brain changes in glaucoma. *Eur J Ophthalmol* 13: S32-S35.
11. Lester M, De Feo F, Douglas GR (2012) Visual field loss morphology in high- and normal-tension glaucoma. *J Ophthalmol* 2012: 327326.
12. Lestak J, Tintěra J, Kynčl M (2011) Changes in the Visual Cortex in Patients with High-Tension Glaucoma. *J Clin Experiment Ophthalmol* S4:002.
13. Lestak J, Nutterova E, Pitrova S (2012) High Tension versus Normal Tension Glaucoma. A Comparison of Structural and Functional Examinations. *J Clin Experiment Ophthalmol* S5: 006.
14. Okuno T, Sugiyama T, Kojima S, Nakajima M, Ikeda T (2004) Diurnal variation in microcirculation of ocular fundus and visual field change in normal-tension glaucoma. *Eye (Lond)* 18: 697-702.
15. Plange N, Remky A, Arend O (2003) Colour Doppler imaging and fluorescein filling defects of the optic disc in normal tension glaucoma. *Br J Ophthalmol* 87: 731-736.
16. Park HY, Jeon SH, Park CK (2012) Enhanced depth imaging detects lamina cribrosa thickness differences in normal tension glaucoma and primary open-angle glaucoma. *Ophthalmology* 119: 10-20.
17. Qing, G, Zhang, S, Wang B (2010) Functional MRI Signal Changes in Primary Visual Cortex Corresponding to the Central Normal Visual Field of Patients with Primary Open-Angle Glaucoma. *Invest Ophthalmol Vis Sci* 51: 4627-4634.
18. Schwenn O, Troost R, Vogel A, Grus F, Beck S, et al. (2002) Ocular pulse amplitude in patients with open angle glaucoma, normal tension glaucoma, and ocular hypertension. *Br J Ophthalmol* 86: 981-984.
19. Shields MB (2008) Normal-tension glaucoma: is it different from primary open-angle glaucoma? *Curr Opin Ophthalmol* 19: 85-88.
20. Shin IH, Kang SY, Hong S, Kim SK, Seong GJ, et al. (2008) Comparison of OCT and HRT findings among normal, normal tension glaucoma, and high tension glaucoma. *Korean J Ophthalmol* 22: 236-241.
21. Smith IELI, Chino YM, Harwerth RS (1993) Retinal inputs to the monkey's lateral geniculate nucleus in experimental glaucoma. *Clin Vis Sci* 8: 113-139.
22. Sung KR, Lee S, Park SB, Choi J, Kim ST, et al. (2009) Twenty-four hour ocular perfusion pressure fluctuation and risk of normal-tension glaucoma progression. *Invest Ophthalmol Vis Sci* 50: 5266-5274.
23. Thonginnetra O, Greenstein VC, Chu D, Liebmann JM, Ritch R, et al. (2010) Normal versus high tension glaucoma: a comparison of functional and structural defects. *J Glaucoma* 19: 151-157.
24. Vickers JC, Hof PR, Schumer RA, Wang RF, Podos SM, et al. (1997) Magnocellular and parvocellular visual pathways are both affected in a macaque monkey model of glaucoma. *Aust N Z J Ophthalmol* 25: 239-243.
25. Weber AJ, Chen H, Hubbard WC, Kaufman PL (2000) Experimental glaucoma and cell size, density, and number in the primate lateral geniculate nucleus. *Invest Ophthalmol Vis Sci* 41: 1370-1379.
26. Yucel YH, Zhang Q, Weinreb RN, Kaufman PL, Gupta N (2001) Atrophy of relay neurons in magno- and parvocellular layers in the lateral geniculate nucleus in experimental glaucoma. *Invest Ophthalmol Vis Sci* 42: 3216-3222.
27. Yucel YH, Zhang Q, Weinreb RN, Kaufman PL, Gupta N (2003) Effects of retinal ganglion cell loss on magno-, parvo-, koniocellular pathways in the lateral geniculate nucleus and visual cortex in glaucoma. *Prog Retin Eye Res* 22: 465-481.

This article was originally published in a special issue, **Glaucoma** handled by Editor(s). Dr. Zaher Sbeity, University of Düsseldorf Teaching Hospital Mulheim, Germany

Submit your next manuscript and get advantages of OMICS Group submissions

Unique features:

- User friendly/feasible website-translation of your paper to 50 world's leading languages
- Audio Version of published paper
- Digital articles to share and explore

Special features:

- 200 Open Access Journals
- 15,000 editorial team
- 21 days rapid review process
- Quality and quick editorial, review and publication processing
- Indexing at PubMed (partial), Scopus, DOAJ, EBSCO, Index Copernicus and Google Scholar etc
- Sharing Option: Social Networking Enabled
- Authors, Reviewers and Editors rewarded with online Scientific Credits
- Better discount for your subsequent articles

Submit your manuscript at: www.editorialmanager.com/clinicalgroup

